

Development of Patient Assistive Tool for Detection of Abnormalities in Kidney

T. Mangayarkarasi^{1*} and D. Najumnissa Jamal²

¹Department of Instrumentation and Control Engineering, Sri Sai Ram Engineering College, B.S. Abdur Rahman University, Chennai – 600048, Tamil Nadu, India; hod.ice@sairam.edu.in

²Department of Instrumentation and Control Engineering, B.S. Abdur Rahman University, Chennai – 600048, Tamil Nadu, India; najumnissa.d@bsauniv.ac.in

Abstract

Ultrasound Scan is the most popular and cheapest imaging technique which is used as a preliminary investigating tool by the doctors nowadays. In this regard, development of a computer aided assistive tool is utmost necessary to create a user friendly interface for the patients to expose them to basic treatment procedures available in case of abnormalities found in the Ultrasound Scan. An easy and better understanding of the impressions given in the scan is vital for further treatment procedures. As a first step towards creating a complete computer aided treatment assistive tool, the abnormalities detection in kidney ultrasound images is taken up as a primary goal in this paper. The most common renal problems that can be identified in the ultrasound images are renal stones or calculi, cyst and infections. A Graphical User Interface (GUI) is developed to display the count and size of calculi present in kidney. The GUI also specifies the presence of cyst. Ultrasound renal images are preprocessed and the speckle noises are removed using median filter. MATLAB software is used to perform the image processing. Segmentation is performed using Thresholding and Seeded Region growing algorithms. The algorithms are compared based on the statistical features which are extracted from the segmented images and the Seeded Region Growing algorithm is found to be the best since the Mean Square Error (MSE) and Standard Deviation (SD) are comparatively less. The appropriate treatment procedure obtained from an expert urologist is suggested in the GUI depending upon the size of the calculi.

Keywords: Mean Square Error, Seeded Region Growing Algorithm, Standard Deviation, Thresholding Algorithm, Ultrasound Scan

1. Introduction

There are many different forms of renal abnormalities associated with the renal system such as renal calculi, renal cyst and kidney infection, end stage renal failure and polycystic kidney disease. The most common renal abnormality is the presence of renal calculi or stone in any part of the renal system like ureter, kidney or bladder. Doctors look in for information such as size, location of kidney stones, Presence of infection or cyst as the treatment procedure greatly depends on these factors. In this paper a GUI is developed which can act as a second opinion tool for the patients to process the kidney

ultrasound images and to provide relevant information for further treatment.

Several algorithms have been proposed for ultrasound kidney image diagnosis for calculi¹ and to find the size of the calculi. Contour based Squared Euclidean Distance (CSED) segmentation method² has also been proposed and initially the pre-processing techniques are applied to reduce the noise from the ultra sound kidney images. But in this paper user friendly GUI is created as an initial second opinion tool to help the patient in understanding the problem and treatment procedure. Exciting algorithms are used to detect the size of the calculi, number of calculus present and the treatment procedure that shall be carried out by an expert urologist is also suggested.

*Author for correspondence

Thus the main aim is to reduce the time taken for the patient to decide on the best treatment available and different procedures carried out in treating the renal problem.

2. Renal Abnormalities and Treatments

2.1 Types of Renal Problems and Kidney Stones

Calcium stones are most common and they are made up of calcium oxalate, phosphate. Uric acid stones are most common in men than in women. Struvite stones are most common in women with urinary tract infection and are quite painful and large. Cysteine stones are most rare and occur in both men and women with genetic disorder. Renal cyst is a round pouch of smooth, thin-walled tissue or a closed pocket that is filled with fluid. Hydronephrosis is a condition that occurs when one kidney is swollen due to failure of normal drainage of urine from the kidney to the bladder. It is due to blockage or obstruction in the urinary tract.

2.2 Treatments Available

2.2.1 Extracorporeal Shock Wave Lithotripsy (ESWL)

Lithotripsy is a procedure that uses shock waves to break up stones in the kidney, bladder, or ureter after the procedure, the tiny pieces of stones pass out of patient's body in urine. ESWL is the most common way of treating kidney stones that cannot pass through the urine. It uses X-rays or Ultrasound to locate the kidney stone. It is a form of treatment that sends shock waves of energy to break the stone into smaller pieces so that it can pass through the urine. ESWL is up to 99% effective for stones that are up to 20 mm in diameter.

2.2.2 Ureterorenoscopy

This treatment is preferred for stones present in ureter. It is sometimes known as Retrograde Intra Renal Surgery (RIRS). It involves passing a long thin telescope called an ureteroscope through the urethra and into the bladder and then passed into the ureter. The treatment is performed under general anesthesia. It is 50 to 80 percentages effective for stones up to 15 mm.

2.2.3 Percutaneous Nephrolithotomy (PCNL)

It involves the use of a thin telescopic instrument called a nephroscope. An incision is made in the back and the nephroscope is passed through the incision and then passed through the kidney. The treatment is performed under general anesthesia for larger stones and the stone is either pulled out or broken into smaller pieces using a laser or pneumatic energy. PCNL is 86% effective for stones that are 21 to 30 mm in diameter.

3. Proposed System

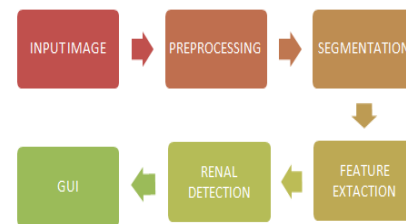


Figure 1. Block diagram of the proposed system.

3.1 Steps Involved in Detection of Renal Abnormalities

Pre-Processing median filter is applied to remove the speckle noise present in Ultrasound Kidney images and the input image is enhanced. Two segmentation algorithms are applied to the processed images-Seeded Region growing algorithm and thresholding segmentation algorithm are applied. Statistical features are extracted from the segmented image. From the segmented image, the renal abnormalities like stone and cyst are detected and the appropriate size and suitable treatment is suggested. User-friendly GUI is created to display the number, size and treatment procedure.

3.2 Input Images

The real time ultrasound kidney images with stone and cyst were obtained from Saanvi fertility clinic and urology center Chennai. As an initial work only 7 images were obtained.

The specifications of ultrasound scan machine - Mindray is listed below.

Table 1. Specifications of scan machine

Portable or cart based	Portable
Optional trolley	Yes
Monitor screen size	15"
Battery power available	Optional
Image Storage	Yes- export to
DICOM networking	Optional
User configurable pre-sets	Yes
Cardiology measurement packages	Yes
Customizable user measurements	Yes
Width	415 mm
Depth	378 mm
Height	190 mm
Weight	7.7 Kg

3.3 Pre Processing using Median Filter

Filtering is done by median filter because preserving the distinct edges of medical images is very important. Procedure for implementing median filter: Median filter selects the middle value in a sorted list. The two steps are the pixel value is read and the list is sorted. The median value is chosen. The value replaces the central value of the mask. The window is moved by one pixel and the process is repeated.

3.4 Image Enhancement

Image Enhancement is carried out using Contrast Limited Adaptive Histogram Equalization method (CLAHE). The CLAHE algorithm partitions the images into contextual regions and applies the histogram equalization to each one. This evens out the distribution of used grey values and thus makes hidden features of the image more visible. The full grey spectrum is used to express the image.

3.5 Image Segmentation

Image segmentation is the process of dividing an image into multiple parts. The ROI is the renal calculi in the kidney ultrasound image. Image segmentation algorithms are based on either discontinuity principle or similarity principle. Semi-automatic segmentation is carried out. It is a combination of automatic and manual algorithms. In the initial stages intervention is required. The initial seed point indicating the ROI is provided. Then the extraction

process is carried out automatically. Region growing techniques and thresholding segmentation are semi-automatic algorithms where the initial seeds are given in the region that needs to be segmented. However, the program process is automatic.

4. Algorithms

4.1 Thresholding Segmentation Techniques

Thresholding is the simplest method of image segmentation.

Step 1: Read the input image.

Step 2: Convert the true color image to gray scale image.

Step 3: Find the x and y coordinates in the image and choose a threshold value.

Step 4: Find the x and y coordinates of the stone and choose the threshold value accordingly.

Step 5: Threshold value of the stone is given a value 1 and the other pixels in the image are given a value 0.

Step 6: In this way, the region of interest (stone) is segmented.

4.2 Seeded Region Growing Segmentation Algorithm

Step 1: Read the input image

Step 2: Convert the input image into grayscale image.

Step 3: Select an initial seed point from the ROI.

Step 4: Compare the seed point pixel value with the neighboring pixel values.

Step 5: If those neighboring pixel values fall within the threshold values, then add it to the ROI. Else, compare it with the other neighboring pixel values.

Step 6: Selected pixels compose the ROI.

5. Results and Discussions

The above Table illustrates the metrics which have been obtained from the original image and the segmented images. It is found that MSE and SD are less for the seeded region growing technique. The Seeded region growing Algorithm performs better than the Thresholding technique in the detection of stones and cyst in the Ultrasound kidney images.

The above GUI displays the information like number of stones present, size of the stone and the appropriate treatment as suggested by a leading Urologist. The presence of single stone, multiple stones and Cyst is detected

Table 2. Comparison of Performance metrics

Parameters	Input Image	Seeded Region Growing	The sholding Algorithm
MEAN	55.8067	28.3250	25.1789
SD	59.3761	21.0526	33.7149
MODE	1.0000	17.0000	0.0000
MSE	0.0027	0.0003	0.0021
MEDIAN	119.0000	23.0000	43.0000
ENTROPY	5.5800	5.0600	4.9084

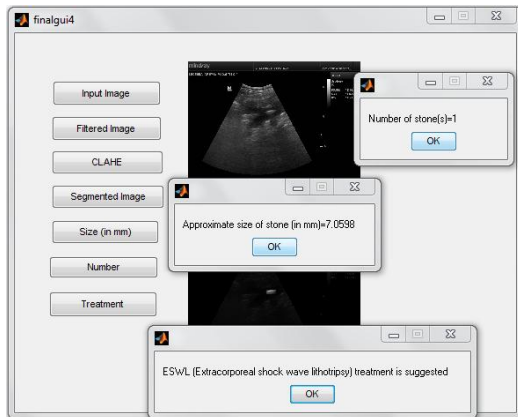
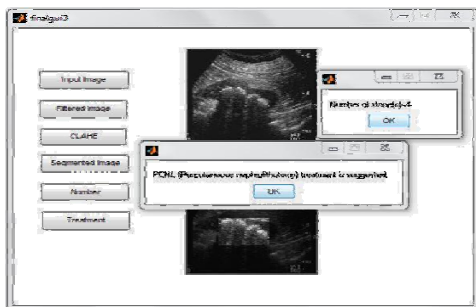
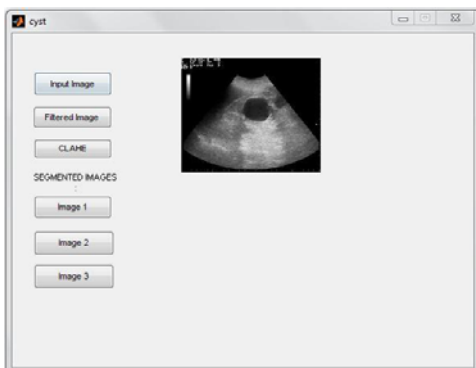
**Figure 2.** GUI-single stone.**Figure 3.** GUI-multiple stone**Figure 4.** GUI-Cyst.**Table 3.** Details of Processed image and accuracy achieved

Image Processed Findings			% Of Accuracy With Doctor's Observation		Suggested Treatment
Single Stone	Size (in mm)	Algorithm Used	Size (in mm)	Accuracy (in %)	
Yes	6.34	Threshold Method	7	90.58	ESWL
Yes	7.05	Seeded Region Method	7	99.28	ESWL
Yes	3.01	Seeded Region Method	3	99.66	ESWL
Multiple Stones	Size (in mm)	Algorithm Used	Size (in mm)	Accuracy (in %)	
Yes	>30	Threshold Method	32	93.75	

by Ultrasound image processing and user friendly information is given to the patients in order to reduce the time taken for the patients in seeking a second opinion.

It is inferred from the above results that a maximum accuracy of 99.66% is achieved in seeded region growing segmentation method.

In this initial work, I have investigated the simplest algorithms to detect kidney stones and cyst in the ultrasound kidney images. The work is based on semiautomatic algorithms like Thresholding and Seeded Region Growing segmentation techniques. Statistical features such as MSE (Mean Square Error), Mean, Median, Entropy, SD (Standard Deviation) are extracted from the input as well as the segmented images.

A user friendly GUI is created, which displays the size, number of the stone and the treatment to be followed. The size of the stone and the treatment suggested in the GUI are compared with doctor's observations and the results are proved to be accurate enough. The above proposed method can be extended as a user friendly mobile application where after the input images are scanned, the doctor's impressions can be sent as a message to the patient. The work can be further extended with automatic algorithms for complete list of abnormalities that can be easily detected from ultrasound kidney images and a complete second opinion tool for the patient can be developed.

6. Acknowledgment

The real time images for the work were obtained from Saanvi urology and stone center Chennai. Thanks to

Dr. G. Vezhaventhan Urologist, Chennai for his valuable guidance, suggestions and verification extended to validate the results obtained.

7. References

1. Sridhar S. Segmentation of ureteric and bladder in ultrasound images. *Journal of Computer Science*. 2012; 8(5):716–20.
2. Tamilselvi PR. Segmentation of renal calculi using squared euclidean distance method. *International Journal of Scientific Engineering and Technology*. 2013; 2(7):651–5
3. Khan AM, Ravi S. Image segmentation methods: A comparative study. *International Journal of Soft Computing and Engineering (IJSCE)*. 2013; 3(4).
4. Tamilselvi PR, Thangaraj P. Computer aided diagnosis system for stone detection and early detection of kidney stones. *Journal of Computer Science*. 2011; 7(2):250–4..
5. Tamilselvi PR. Effective segmentation approaches for renal Calculi Segmentation. *International Journal of Science and Research (IJSR)*.
6. Sridhar S. *Digital image processing*. Oxford University Press; 2011.
7. Khandpur RS. *Handbook of biomedical instrumentation*.