www.djas.co.in
ISSN No-2321-1482

DJAS 5(II), 76-80, 2017

REVIEW ARTICLE

Dental JOURNAL
of Advance Studies

RESIDUAL RIDGE RESORPTION– REVISITED

Ramandeep Kaur[1], Manjit Kumar[2], Neha Jindal[3], Isha Badalia[4]
[1]PG Student, Dept. of Prosthodontics, Bhojia Dental College and Hospital, Himachal Pradesh, India.
[2]Professor and Head, Dept. of Prosthodontics, Bhojia Dental College and Hospital, Himachal Pradesh, India
[3]PG Student, Dept of Prosthodontics, Bhojia Dental College and Hospital, Himachal Pradesh, India
[5]PG Student, Dept of Prosthodontics, Bhojia Dental College and Hospital, Himachal Pradesh, India

ABSTRACT

The Residual Ridge Resorption (RRR) is a major unsolved oral disease with unidentifiable characteristics and unwanted squealae causing physical, psychologic, and economic problems for millions of people all over the world. RRR is basically a term used to describe a condition that affects the alveolar ridge after tooth extractions even after healing of the wounds. RRR is a chronic, progressive, irreversible, and disabling disease, probably of multifactorial origin. The possible etiological factors could be divided into four categories: anatomic, metabolic, functional, and prosthetic. The primary structural change in the reduction of residual ridges is the loss of bone or reduction in the size of bony ridge under mucoperiosteum. The reduction in the ridge mainly occurs labially, lingually and on the crest. The reduction of the residual ridge leads to a variety of stages of ridge form, including high well-rounded, knife-edge, low well-rounded, and depressed forms.Alveolar bone atrophy is cumulative and irreversible, since alveolar bone cannot regenerate. It differs from one individual to the other. It also varies at different times and different sites. Some authors feel RRR as a normal physiologic process and not a disease but the cost in economic and human terms makes RRR as a major oral disease that can be described in terms of its pathology, pathophysiology, pathogenesis, epidemiology, etiology, treatment and prevention.

Keywords: Residual ridge resorption, alveolar bone,mucoperiosteum

INTRODUCTION

Anatomic changes will invariably take place within the alveolar processes of the jaws following dental extractions. When the teeth are present, the pressures exerted on these structures during contraction of the masticatory muscles are transmitted in the form of tension to the bone by the periodontal membrane. This type of stress is acceptable for the alveolar bone and may even serve as a stimulus for alveolar bone remodelling. Once the teeth are extracted, the whole distribution of forces is changed. The load is not directed to the entire bone, but is applied only on its surface. Alveolar bone can only tolerate this compression to a certain extent. The long-term effect of dentures over bone is the atrophy of the residual alveolar ridge or what Atwood calls reduction of residual ridges (RRR).[1]

Corresponding Author:
Ramandeep Kaur
E-mail:
raman000q@gmail.com
Received: 15th April 2017
Accepted: 23rd June 2017
Online: 20th September 2017

DEFINITION

Residual Ridge Resorption- A term used for the diminishing quantity and quality of the residual ridge after the teeth are removed.

Residual Ridge – The portion of the residual bone and its soft tissue covering that remains after removal of teeth.

Residual Bone – The component of maxillary and mandibular bone, once used to support the roots of the teeth, that remains after teeth are lost

PATHOLOGY

Gross Pathology

The primary structural change in the reduction of residual ridges is the loss of bone or reduction in the size of the bony ridge under mucoperiosteum[2]. Numerous Longitudinal cephalometric studies have provided excellent visualization of the gross patterns of the bone loss. The

superimposition of tracings of cephalograms made in various studies clearly shows that reduction of the ridge occurs labially, on the crest, and lingually. The rate of reduction and the total amount of bone removed in this disease vary from individual to individual, within the same individual at different times, and even at the same time in different parts of the ridge[3].

There are 5 patterns of resorption[4](Figure 1)

Group I – minor ridge remodelling

Group II - sharp atrophic residual ridge

Group III – basal bone ridge

Group IV – resorption of basal bone

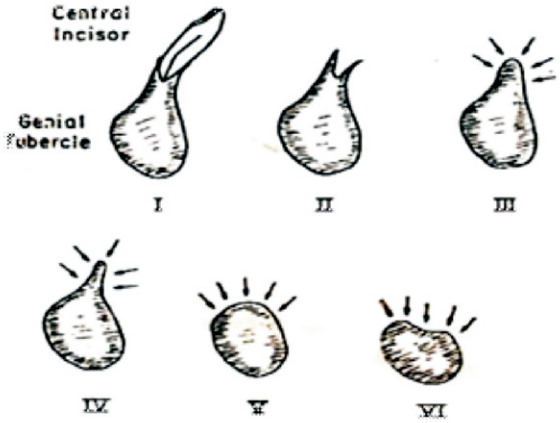

Figure 1: Six orders of mandibular anterior residual ridge

In some situations, RRR leaves redundant mucoperiosteum while in others it appears to be well-attached mucoperiosteum with no redundant tissue over the resorbed ridge. Similarly, the soft tissue overlying the residual ridges that have undergone RRR may or may not be inflamed, oedematous, ulcerated or indented.

In order to provide a simplified method of describing RRR pathology ,a system of six residual ridges have been described .The reduction of the residual ridge leads to a variety of stages of ridge form, including high well-rounded, knife-edge, low well-rounded, and depressed forms[4](Fig. 2,3).

Another gross finding is that while external cortical surfaces of mandible and maxilla are uniformly smooth, the crestal areas may show porosities and irregularities.

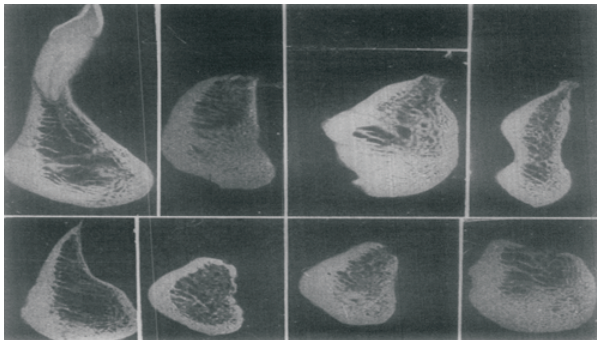

Figure 2: Microradiographs of midsagittal sections of mandibles illustrating various orders of residual ridge form.

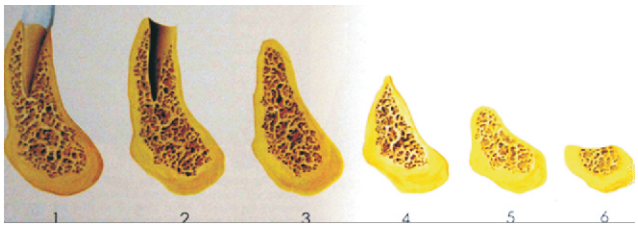

Figure 3: Atwood's Classification

Microscopic Pathology

Microscopic studies have revealed evidence of osteoclastic activity on external surface of the crest of residual ridge. The scalloped margins of Howship's lacunae contain visible osteoclasts[5]. Frequently,the scalloped external surface seems inactive,without visible bone resorbing cells and is covered by nonosteogenic periosteum. Microscopic studies of mucoperiosteum has shown varying degree of keratinisation,acanthosis, edema and varying degree of inflammatory cells such as lymphocytes and plasma cells[3](Figure 4).

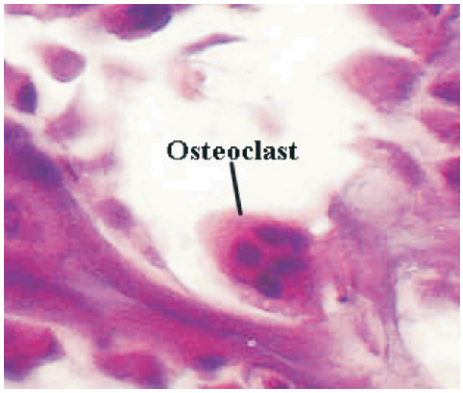

Figure 4: Microscopic pathology of residual ridge resorption

PATHOPHYSIOLOGY

The amount of bone loss may be greater than the original thickness of the cortical bone. This mean that, in such patients, new bone is laid down internally while resorption occurs externally. The bone remodelling process does not always work with equal success is shown in the many patients in whom residual ridge crest has no cortical layer. This process of external resorption and endosteal deposition is not unique to RRR, for it is similar to one phase of bone growth as described by Enlow.[6] Growth of a long bone such as the tibia is much more complicated than the periosteal deposition of bone. As long bones grow longer, they are constantly reshaped in three dimensions.

This narrowing of a portion of a bone is achieved by external rcsorption. Such external resorption does not occur without endosteal deposition. If no new bone were laid downendosteally, the cortex would become progressively thinner until it completely disappears. The structural product of this inward growth is called "endosteal bone" and is characterized either by a convoluted whorled appearance (when growth occurs into a trabecular area) or by a zone of even, regular, uninterrupted circumferential lamellae (when bone is laid down in layers on the endosteal side of smooth cortical bone). In each instance, the configuration of the new bone is dependent upon the configuration of the bony surfaces on which the deposition occurs.

PATHOGENESIS

RRR is chronic, progressive, cumulative and irreversible. Autonomous regrowth has not be reported. The annual increments of bone loss have a cumulative effect leaving less and less residual ridge.

In general, the rate of RRR varies between different individuals. Within a given individual the rate is usually most rapid in the first 6 months following extraction. An interesting history of one patient shows a rapid resorption rate in the early months in both the upper and lower anterior ridge height. Whereas, the upper ridge showed no measurable change after the first 3 years, the lower ridges showed a continuing RRR at a steady rate (0.4 mm. per year) over 15 year period. The vertical bone loss of the anterior part of the ridge in 19 years was 3.mm. in the maxillae and 14.5 mm. in the mandible[7].

The reduction of residual ridges seems to be potentially unlimited. Both cancellous and trabecular bone resorbed no matter how well they are calcilfied. RRR can go below mucobuccal fold, the muscle attachments, the genial tubercles, the mylohyoid ridge, and the level of periapical bone.

ETIOLOGY

It is entirely possible that RRR is a multifactorial disease and that the rate of RRR depends not on one single factor but on the concurrence of two or more factors, which may be called cofactors. Some years ago, it was suggested that, for convenience, possible factors could be divided into four categories: anatomic, metabolic, functional, and prosthetic.

Anatomic factors

It includes size and shape of the ridge, type of bone, type of mucoperiosteum, bone quality and form before extraction. It is postulated that RRR is directly proportional to anatomic factors.

1) RRR varies with quality and quantity of the bone of residual ridge. If there is more bone there will be more resorption.
2) We should also try to evaluate the present status of the residual ridge to determine what has gone before. If a ridge has existed as high and well-rounded for several years it will continue to do like so.
3) Large well rounded ridges and broad palates seem to be favourable anatomic factors
4) Another anatomic factor is density. However, for the density at given moment does not signify the current metabolic activity of the bone and bone can be resorbed by the osteoclastic activity regardless of its calcification.

A study done by Atwood D.A and Coy W. A. revealed that bone reduction in maxillae was 0.1 mm per year and mandible was 0.4 mm per year, a fourfold increase (Figure 5). No strong correlation between resorption and co–factors of anatomy, sex, age, menopause, stability, hour's denture is worn, bone density and reduction of residual ridges.[2]

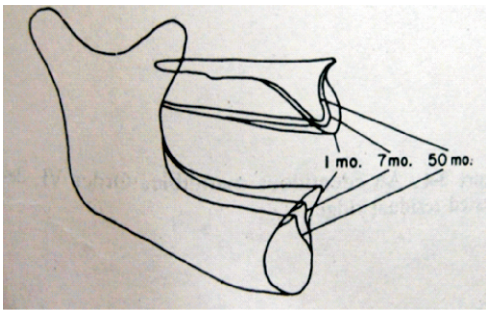

Figure 5: Tracings of lateral cephalograms showing the gross reduction of bone in size and shapeoccuring on the labial, crestal, and lingual aspects of the residual ridge

According to study by Mercier. P and la Fontant. R, they concluded[7]that longer the face, the more alveolar bone there is and the less chance there is for an individual to reach a stage of severe atrophy in wearing dentures. This statement does not take into account the rate of resorption of each individual, since a long face may resorb faster than a shorter face due to factors other than the morphology of the face.

If the vertical dimension of occlusion is less, there will be more compressive forces applied on the residual ridges and the greater will be the chances for an individual with a less vertical dimension of occlusion to reach the stage of extremely severe atrophy with dentures, especially for the mandible.

Metabolic factors

They include such things as age, sex, hormonal imbalance, osteoporosis. In older individuals bone resorption is more as compared to bone formation. The ridge atrophy would be in harmony with the potential senile atrophy of old age (Mercier.P)[7]. All values used to study ridge resorption are higher for male groups as compared to female. Generally females have high predilection of resorption because of hormonal imbalance.

Certain local bone resorbing factors are also important. They include:[8]

a) Endotoxins – from dental plaque (plaque can occur in edentulous mouth, in patients who do not clean their dentures)
b) Osteoclast activating factor
c) Prostaglandins
d) Human gingival bone resorption stimulating factor
e) Heparin – cofactor in bone resorption secreted by the mast cells
f) Others include trauma under ill-fitting denture, which leads to increased or decreased vascularity and changes in oxygen tension.
g) Systemic factors – include circulating oestrogen, thyroxine, growth hormone, androgens, calcium, phosphorus, vitamin D, proteins and fluorides .

However no correlation between rate of RRR and the presence of osteoporosis in mandible exists.

According to Esa Klemetti et al the duration of edentulousness and skeletal mineral status are important factors in the resorption of residual ridges. The location of the incisive papilla and the thickness of the ridge on facial side of the palatogingival margin are associated with these two factors.

Mechanical factors

Force is an cofactor in RRR that can be expressed as RRR force. If considering force not only the amount of force but also the frequency of force, the duration of force, the area over which the force is distributed, the damping effect of the underlying tissue.[7]Cutright et al also calculated the variety of both positive and negative forces on the residual ridges from activities such as smoking, talking, counting and biting. As noted ,there is tendency for there to be more RRR in the mandible than in maxilla due to difference in their surface area.

The amount of force applied to the bone may be affected inversely by the damping effect or the energy absorption. The damping effect may take place in mucoperiosteum and since mucoperiosteum varies in its viscoelastic properties patient from patient and from maxilla to mandible, its energy absorption qualities may also influence the rate of RRR. The fact that maxillary residual ridge is frequently broader, flatter and more cancellous than mandible so it may be considered as a cofactor in differences in the RRR of the jaws. Gibbs et al found that overall loading of the edentulous mandible is considerably less than in dentulous mandible.

Prosthetic factors

These factors include:

a) Broad area coverage – to reduce force per unit area

b) Decreased number of dental units

c) Decreased buccolingual width of the teeth

d) Improved tooth form –to decrease the amount of force required to penetrate bolus of food

e) Avoidance of inclined planes

f) Centralization of occlusal contacts –to increase stability

g) Provision of adequate tongue room for proper speech

h) Adequate interocclusal distance

Various clinical studies have been attempted to correlate one or more factors with rate of RRR.

TREATMENT

RRR is complex multifactorial process so ideally we treat this by preventing it.

1) Improving patients denture foundation and ridge relation:

a) Non-Surgical methods – a) rest for supporting tissue by using soft liner or by massaging

b) Correction of VD and occlusion

c) Jaw exercises

d) Surgical methods – performing various preprosthetic surgeries such as removal of any bony prominences, removing unfavourable frenum attachments or epulisfissuratum or papillomatosis and any pressure on mental foramen. Apart from this localised or generalised hyperplastic replacement of resorbed ridges can also be done.

2) Enlargement of denture bearing areas through ridge augmentation and vestibuloplasty can also be done.

3) Root tooth analogues can also be placed by means of osseointegrated implants – after dental extractions, the residual alveolar bone undergoes a period of accelerated resorption, followed by bone loss. The use of implant supported fixed prosthesis can be treatment of choice to prevent residual ridge resorption.

REFERENCES

1. Atwood, D. A. Cephalometric Study of the Clinical Rest Position Following Removal of Occlusal Contacts, Part III. Clinical Factors Related to Variability of the Clinical Rest Position Following the Removal of Occlusal Contacts, J. Prosthet. Dent. 8: 693-708,1958.
2. Atwood, D. A. A Cephalometric Study of the Clinical Rest Position of the Mandible. Part I. The Variability of the Clinical Rest Position Following the Removal of Occlusal Contacts, J. Prosthet. Dent. 6: 504-519, 1956.
3. Atwood, D. A: Reduction of residual ridges : A major oral disease entity. J. Prosthet. Dent. 26: 266-269, 1971.
4. Atwood, D. A.: Post extraction Changes in the Adult Mandible as Illustrated by Microradiographs of Midsagittal Sections and Serial Ccphalometric Roentgenograms, J. Prosthet. Dent. 13: 810-824, 1963.
5. The Variability in the Rate of Bone Loss Following the Removal of Occlusal Contacts, J. Prosthet. Dent. 7: 544-552,
6. Enlow. D. H. The principles of bone remodelling. Springfield, III.1963. Charles C Thomas.
7. Extraction. Part IV. InterseptalAlveolectomy and Closed Face Immediate Denture Treatment, Aust. Dent. J. 9: 312, 1961.
8. Atwood, D. A.: A Cephalometric Study of the Clinical Rest Position of the Mandible.Part. II.
9. Atwood, D. A., Coy W.A. Clinical, Cephalometric and densitometric study of reduction of residual ridges., J. Prosthet. Dent. 26: 280-295, 1971.
10. Mercier Paul, Lafontant Roger. Residual alveolar ridge atrophy: Classification and influence of facial morphology.J. Prosthet. Dent. 41: 90-100, 1979.
11. Atwood, D. A: Some Clinical Factors Related to Rate of Resorption of Residual Ridges,J. Prosthet. Dent. 12: 441-450, 1962.
12. Baylink D.J. et al. Systemic factors in alveolar bone loss. J Prosthet Dent; 31: 486-505, 1974.
13. WicalK.E.,Scope C.C. Studies of residual ridge resorption. Part II. The relationship of dietary calcium and phosphorus tpo residual ridge resorption. J Prosthet Dent; 32:13-22, 1974.